

Access this article online

Quick Response Code:



Website:
www.eurasianjpulmonol.com

DOI:
10.4103/ejop.ejop_67_19

Thoracic ultrasonography in the evaluation of lung parenchyma in interstitial lung diseases

Coşkun Doğan, Nesrin Kırıl, Elif Torun Parmaksız, Ali Fidan, Benan Çağlayan¹, Banu Salepçi², Sevda Şener Cömert

ORCID:

Coşkun Doğan: <https://orcid.org/0000-0002-6948-5187>
Nesrin Kırıl: <https://orcid.org/0000-0002-7524-2501>
Elif Torun Parmaksız: <https://orcid.org/0000-0002-3670-8508>
Ali Fidan: <https://orcid.org/0000-0003-3449-6916>
Benan Çağlayan: <https://orcid.org/0000-0002-6131-157X>
Banu Salepçi: <https://orcid.org/0000-0003-1217-019X>
Sevda Şener Cömert: <https://orcid.org/0000-0002-3334-688X>

Abstract:

PURPOSE: The changes due to interstitial lung diseases (ILDs) in the lung parenchyma reveal comet tail artifact (CTA) that is defined on ultrasonography (USG), and is a type of reverberation artifact. We planned to investigate the significance of thoracic USG in the evaluation of the effect of ILD on pulmonary tissues in the present study.

MATERIALS AND METHODS: The present cross-sectional study included patients diagnosed with ILD, and the control group between January 2016 and December 2017, high resolution computed tomography (HRCT) findings (the severity and extension scores for HRCT), pulmonary function tests, and pulmonary function tests and carbon monoxide diffusion test (PFT-DLCO) findings of all patients were recorded. Then, the number of CTAs detected on thoracic USG was recorded by a different pulmonologist. The data of the two groups were compared with each other.

RESULTS: Thirty-six (50.7%) patients and 35 (49.3%) healthy controls were included in the study. The mean number of CTA in the control group was 25 ± 6.4 while the number of CTA in the ILD group was 68.3 ± 16.2 ($P < 0.001$). Negative correlations were found between the total CTA and DLCO, DLCO%, forced vital capacity (FVC), and FVC% values ($P < 0.001$). Positive correlation was found between the total number of CTA and the total HRCT score ($P: 0.01$). The sensitivity of B-lines on USG was 94.4%, and specificity was 97.1% with a cutoff value of 39.5 to diagnose interstitial involvement.

CONCLUSION: Thoracic USG may be a good diagnostic tool for diseases that commonly involve the lung interstitium such as ILD.

Keywords:

Comet-tail artifact, interstitial lung diseases, thoracic ultrasonography

Introduction

Interstitial lung diseases (ILDs) are a group of more than 100 diseases with high mortality and morbidity where the lung parenchyma is diffusely affected.^[1] What

ever the reason in the emergence of the ILDs, there are two generally accepted phases: the first is the alveolitis phase that develops with the inflammatory cells accumulating in the interstitial region, and the second is the fibrosis phase which develops with the damage in the interstitial tissue occurring

This is an open access journal, and articles are distributed under the terms of the Creative Commons Attribution-NonCommercial-ShareAlike 4.0 License, which allows others to remix, tweak, and build upon the work non-commercially, as long as appropriate credit is given and the new creations are licensed under the identical terms.

For reprints contact: reprints@medknow.com

How to cite this article: Doğan C, Kırıl N, Parmaksız ET, Fidan A, Çağlayan B, Salepçi B, *et al.* Thoracic ultrasonography in the evaluation of lung parenchyma in interstitial lung diseases. *Eurasian J Pulmonol* 2020;22:104-11.

Department of
Chest Diseases,
Dr. Lütfi Kırdar Kartal
Training and Research
Hospital, ¹Department
of Chest Diseases, Koç
University Faculty of
Medicine, ²Department of
Chest Diseases, Yeditepe
University Faculty of
Medicine, Istanbul, Turkey

Address for correspondence:

Dr. Coşkun Doğan,
Neslişah Street, Teknik
Yapı Up City Apartment,
B2 Block Flat Nr: 40 Uğur
Mumcu, Kartal, Istanbul,
Turkey.
E-mail: [coskund24@
hotmail.com](mailto:coskund24@hotmail.com)

Received: 08-08-2019

Revised: 10-11-2020

Accepted: 27-03-2020

Published: 31-08-2020

secondary to the alveolitis phase, and with the repair process of this damage.^[2] The best radiologic method in ILDs at present is the high-resolution computed tomography (HRCT). The main radiologic reflections of the alveolitis and fibrotic phases on HRCT are the ground glass densities, mosaic pattern, honey-comb appearance, interlobular septal thickenings, and the nodules.^[3]

The main principle of the ultrasonography (USG) is to create an image on the monitor with the back reflection of high resonance sound waves that are sent to the tissues with the help of a transducer. Clear images can be obtained from the solid organs because the back reflection of the sound waves is good. However, the lung tissue cannot be well-screened because a healthy lung tissue with no pathologic disease involves air, and the conductivity of air is weak.^[4] Interstitial inflammation, fibrosis, a thickened interstitial surface, and thickened interlobular septa are observed in the disease where the interstitium is diffusely affected.^[5] Specific images may be obtained from the monitor because ultrasonographic sound waves are reflected back from these pathologic regions. The run of sound waves between the tissue and the probe or between two tissues more than once is called reverberation artefact.^[6] The tail appearance which develops due to the encountering of sound waves with the reflective surface, and observed as trapped, and in decreasing ecogenities on the monitor behind the echoes consecutively reflecting to the transducer is called as the comet tail artifact (CTA)^[7] [Figure 1].

Thoracic USG has recently been used in various diagnostic procedures such as in identification of the pleural fluid, thorasynthesis, transthoracic biopsy, and in the insertion of a pleural catheter.^[8] One another rare area of the use of USG is in the diagnosis of diseases where the interstitium is affected.

We planned the present study to remark the usability of an easily, and rapidly accessible, repeatable imaging method of thoracic USG with no requirement of radiation exposure in the evaluation of the parenchymal involvement of lung in ILD with the comparison of the ultrasonographic results (CTA), and HRCT and pulmonary function tests (PFTs)/carbon monoxide diffusion test (PFT-DLCO) results.

Materials and Methods

Patient population

A cross-sectional study was planned in compliance with the International Declaration of Helsinki between January 2016 and December 2017, and the local ethics board approval was granted. Patients who were followed-up in the chest diseases clinic of our hospital with the diagnosis of ILD with clinical, radiological and/

or histopathological symptoms were included in the ILD group, and patients with no clinical finding, and symptom of ILD who underwent HRCT with various symptoms such as the suspicion of bronchiectasis, and HRCT of whom were found normal were included in the healthy-control group. The patients with previous congestive heart failure were excluded from the study.

First, a specialist of chest diseases performed the clinical, radiological, and/or histopathological evaluation of the patients. Clinical investigations, physical examination results, HRCT results, PFT, and DLCO results were recorded.

Then, another specialist of chest diseases who did not know about the diagnosis, and HRCT, and PFT-DLCO results of the patients examined the thorax USG. The numbers of CTA detected on the predetermined anatomical lines on thorax USG were recorded.

Pulmonary function test and carbonmonoxide diffusion tests

The PFT-DLCO tests of the patients were performed in accordance with the guidelines prepared for the standardisation of the PFT by the American Thorax Society, and European Respiratory Society.^[9,10] PFT and DLCO measurements were performed using the Sensor Medics Vi-Ma × 22, Care Fusion, (San Diego, California) device with the “single breath” technique. The value between 80% and 120% expected for each lung was accepted normal, forced vital capacity (FVC), forced expiratory volume in the first second (FEV1), FEV1/FVC values were recorded as liter, and percentaged value. The ratio of DLCO (mL/min/mmHg/Lt) and DLCO/alveolar ventilation (VA) (DLCO/VA,%) was recorded in liters and percentages with normal test values falling between 80 and 120% of the predicted value for each lung volume.

High resolution computed tomography

The images were taken in high resolution with no contrast agent administration after a deep inspirium in all patients as to provide 15 mm table movement, and 120 kV, 200 mA, and section thickness of 2 mm, at 512 × 512 matrix and bone algorithm using a Siemens Medical Solutions-2010 (Forchheim, Germany) device in axial plane from apex until the end of diaphragm. The images were obtained as to provide the window width as 200 Hounsfield unit (HU), and the window level as -700 HU.

The severity and extension scorings were performed for the HRCTs of the patients. The scoring system of Oda *et al.*^[11] was used for the severity scoring, and scoring system of Warrick *et al.*^[12] was used for the scoring of extension. HRCT results were evaluated in a scale between 1 and 4 in severity scoring. Normal HRCT scored 1 point, ground glass density 2 points, traction

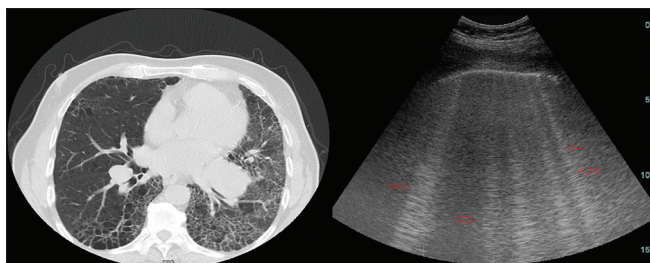


Figure 1: The comet tail artifacts detected using thorax ultrasonography in the patient who had changes on thorax high resolution computed tomography compatible with the interstitial lung disease (comet tail artifacts were demonstrated with red arrow)

bronchiectases 3 points, and honeycomb appearance scored 4 points. Extension scoring was performed in accordance with the number of the involved segment. 1–3 affected bronchopulmonary segments was 1 point, and 4–9 segments scored 2 points, more than 9 affected segments scored 3 points. The total HRCT score was obtained with the addition of severity, and extension scores. The increase of the score ranging between 1 and 6 points demonstrated that the severity of the affected region in HRCT increased. 1–2 points was evaluated as mild, 3–4 points moderate, and 5–6 points were evaluated as severely affected region.

Thorax ultrasonography

The thorax USG was performed by an experienced specialist of chest diseases using the General Electric Logic 7 device, and 3.5 MHz convex probe, and in abdominal mode. Sonographic screening of the thorax was conducted on predefined anatomic lines. One of these anatomic lines was the linea axillaris anterior, passing through the plica axillaris plica axillaris anterior in the lateral side of the thorax; the linea axillaris media, a vertical line originating from the apex of the axilla and the linea axillaris posterior. Finally, in the posterior part of the thorax, the lines were the linea scapularis, a vertical line passing through the angulus inferior scapula, and the linea paravertebralis, which runs parallel to the vertebral column [Figure 2].

Definition of comet tail artefact

Comet tail artefacts were described as the hyperechogenic structures of bundles adjacent to one another which reached to the periphery with the extension of narrow images from visceral pleural region on the monitor when the USG probe is located on the intercostal space.^[6] The region with the most number of CTAs was detected with the longitudinal movement of the probe through the intercostal spaces along each predetermined anatomic line in sitting position of the patient. The CTA numbers in this region was recorded.

Statistical analysis

The statistical analysis was performed using the

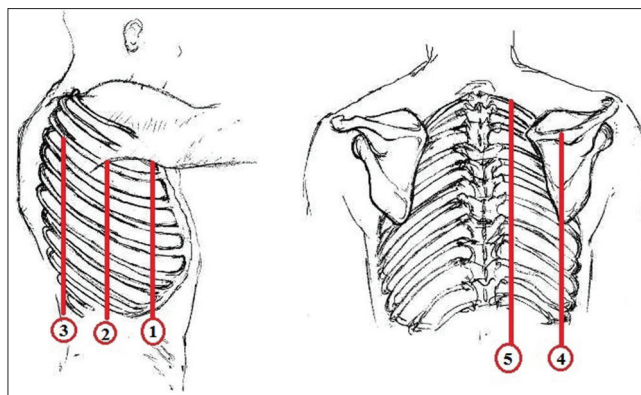


Figure 2: Predefined anatomic lines (1-linea axillaris anterior, 2-linea axillaris media, 3-linea axillaris posterior, 4-linea scapularis, 5-linea para vertebralis)

Statistical Package for the Social Sciences (SPSS) SPSS 17.0 program (released 2008. SPSS Statistic for Windows IBM Inc., Chicago, USA). The continuous variables were given as mean \pm standard deviation, and categorical variables were given as percentage values in the descriptive statistics. The Kolmogorov Smirnov test was used for normal distribution tests. The data of the groups were evaluated using the Chi-square test, and Mann–Whitney U-test, and receiver operating characteristic (ROC) analysis test were used when required, a Pearson correlation analysis was performed to assess the relationship between the PFT-DLCO and HRCT parameters and the CTA numbers of the participants. The correlation coefficient is presented with “*r*” values, and $P < 0.05$ was accepted as the significance value in all tests.

Results

A total of 71 patients consisting of 36 (50.7%) in ILD group, and 35 (49.3%) in control group were included in the study. The mean age in the control group was 40.2 ± 12.8 years, which consisted of 14 (40%) women, and 21 (60%) men; however, the mean age in the ILD group was 60.5 ± 12.4 years consisting of 15 (41.7%) women and 21 (58.3%) men. Twenty-four (68.5%) patients in the control group had no history of smoking, and 11 (31.5%) patients had a history of smoking. The mean smoking history was 2.9 ± 5.9 pack-years, 13 (36.1%) patients in the ILD group had no history of smoking, however, 23 (63.9%) patients had a history of smoking. The mean smoking history in ILD group was 17.6 ± 17.8 pack-years ($P < 0.001$). The investigation of the ILD diagnosis of the patients revealed that 17 (47.2%) patients were diagnosed with idiopathic pulmonary fibrosis (IPF), 7 (19.4%) patients were diagnosed with collagen tissue disease with the affected lung, 4 (11.1%) patients were diagnosed with hypersensitivity pneumonia, 3 (8.3%) patients were sarcoidosis, and 5 (13.8%) were diagnosed with others (drug toxicity, etc.) [Table 1].

The evaluation of the PFT-DLCO values of patients showed that all other parameters except FEV1/FVC, and DLCO/VA in ILD group was significantly lower compared with the control group ($P < 0.001$) [Table 2].

The most frequently detected HRCT result in ILD group was detected as to the bilateral ground glass densities in 29 (85.3%) patients in evaluation of the HRCT imagings [Table 3]. The HRCT imagings of all patients in the control group were detected normal.

The number of CTA was found statistically significantly higher in ILD group in all predetermined 5 anatomic lines in the evaluation of the USG results of the patients. The mean numbers of CTA in 5 predetermined lines was found as 25 ± 6.4 in the control group, and the mean number of CTA in ILD group was found as 68.3 ± 16.2 ($P < 0.001$) [Table 4].

A negative correlation was detected in the total number of CTA, and DLCO (mL/min/mmHg), and DLCO% values in ILD group ($P < 0.001$, $r: -0.722$), ($P < 0.001$, $r: -0.794$) [Figure 3]. A negative correlation was detected between the total number of CTA, and FVC (L) and FVC % values in ILD group ($P < 0.001$, $r: -0.449$), ($P < 0.001$, $r: -0.534$) [Figure 4].

The distribution of the patients in ILD group in accordance with the HRCT score revealed that 18 (50%) patients were in moderate degree (35 points), and 18 (50%) patients were in severe degree (5–6 points). No patients were found in mild degree. The mean number of CTA of patients in moderate degree was 61.8 ± 16.8 , and the mean numbers of CTA was found 74.7 ± 13.1 in patients with severe degree ($P: 0.023$). A positive correlation was detected between the HRCT score, and CTA numbers in ILD group ($P: 0.01$, $r: 0.426$) [Figure 5].

The cutoff value was found as 39.5 in the ROC analysis performed for identification of the optimal CTA cutoff value for the diagnosis of ultrasonographic-clinical ILD diagnosis (area under the curve [AUC]: 0.979). The sensitivity of USG was measured as 94.4%, and specificity was measured as 97.1%, positive predictive value (PPV) was measured as 96.8%, negative predictive value (NPV) was measured as 94.1% in case of detection of the total number of CTA over 39.5 [Figure 6].

The cutoff value was found as 39.5 in the ROC analysis performed for identifying the optimal CTA cutoff value for DLCO in the diagnosis of patients with the ultrasonographic-spirometric ILD (when the DLCO and FVC % value of 80 and below 80 was accepted that interstitium was affected) (AUC: 0.968). The sensitivity of USG was measured as 94.3%, and specificity as 91.7%, PPV: 94.2%, and NPV: 91.6% when the number of total

Table 1: The demographic data of the patients and the control group

	ILD group (n=36)	Control group (n=35)	P
Age (years±SD)	60.5±12.4	40.2±12.8	<0.001
Sex (female/male), n (%)	15 (41.7)/21 (58.3)	14 (40)/21 (60)	0.918
Smoking history (yes/no)	23 (63.9)/13 (36.1)	11 (31.5)/24 (68.5)	0.015
Smoking (pack-years±SD)	17.6±17.8	2.9±5.9	<0.001
Primary disease, n (%)		-	
IPF	17-47.2		
CTD	7-19.4		
Chronic HP	4-11.1		
Sarcoidosis	3-8.3		
Orther	5-13.8		

SD: Standard deviation, IPF: Idiopathic pulmonary fibrosis, HP: Hypersensitivity pneumonitis, ILD: Interstitial lung diseases, CTD: Collagen tissue diseases

Table 2: Pulmonary function tests-carbonmonoxide diffusion capacity findings in patients with interstitial lung diseases and the control group

PFT-DLCO parameters	ILD group (n=36)	Control group (n=35)	P
FEV1/FVC, mean±SD	78.7±7.5	78.5±8.5	0.885
FEV1 (Lt), mean±SD	2.44±0.8	3.77±0.9	<0.001
%FEV1, mean±SD	77.3±24.7	99.1±12.6	<0.001
FVC (Lt), mean±SD	2.83±0.98	4.32±1	<0.001
%FVC, mean±SD	82.6±20.4	106.3±12.3	<0.001
DLCO (mL/min/mmHg), mean±SD	4.67±1.8	9.83±2	<0.001
%DLCO, mean±SD	56.6±15.7	99.4±14.4	<0.001
DLCO/VA (mL/min/mmHg/Lt), mean±SD	1.51±0.7	1.75±0.28	0.087
%DLCO/VA	92.1±17	108.8±16.7	<0.001

DLCO: Carbonmonoxide diffusion capacity, FVC: Forced vital capacity, FEV1: Forced expiratory volume in 1 s, VA: Alveolar volume, SD: Standard deviation, PFT: Pulmonary function tests, ILD: Interstitial lung diseases

Table 3: High-resolution computed tomography findings in patients with interstitial lung diseases

HRCT findings	n (%)
Bilateral ground glass density	31 (86.1)
Bilateral interlobular septal thickening	23 (63.9)
Bilateral honey-comb	14 (38.8)
Bilateral traction bronchiectasis	12 (33.3)
Bilateral reticularreticulo-nodular appearance	9 (12)
Bilateral mosaic perfusion appearance	6 (16.6)
Others	3 (8.3)

HRCT: High-resolution computed tomography

CTA was higher than 39.5 [Figure 7]. The cutoff value was found as 56 in the ROC analysis performed for identifying the optimal CTA cutoff value for FVC (AUC: 0.803). The sensitivity of USG was measured as 84.2%, and specificity as 73.1%, PPV: 94.7%, NPV: 65.3% in detection of the number of total CTA higher than 56 [Figure 8].

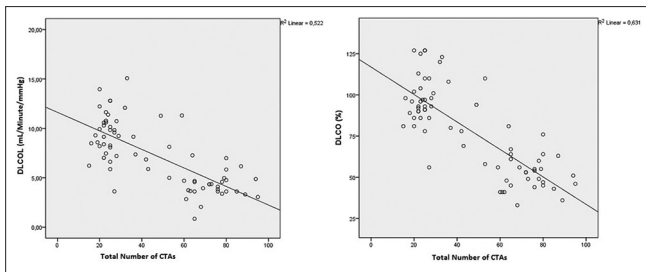


Figure 3: The curve demonstrating the negative correlation between the DLCO, DLCO % value, and total numbers of comet tail artifact of the patients

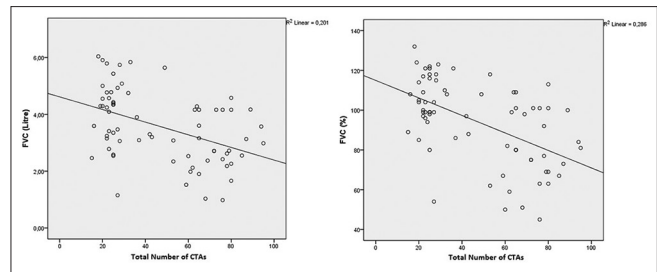


Figure 4: The curve demonstrating the negative correlation between the forced vital capacity, forced vital capacity % value, and total number of comet tail artifact

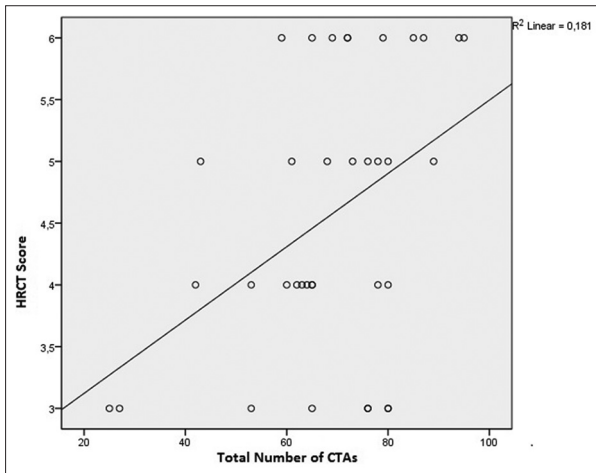


Figure 5: The curve demonstrating the positive correlation between high resolution computed tomography score, and total numbers of comet tail artifact of the patients

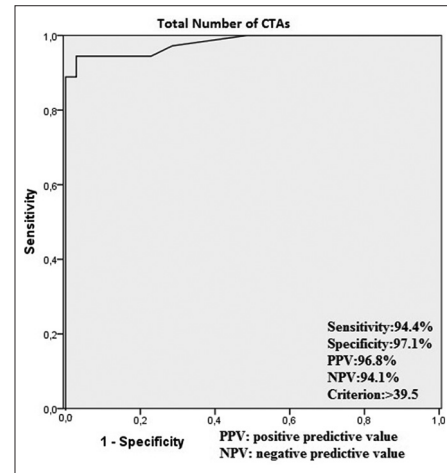


Figure 6: The curve demonstrating the optimal comet tail artifact cut-off value

The specificity of USG in diagnosing ultrasonographic-clinical ILD was found higher than FVC and DLCO (97.1%, 91.7%, 73.1%, respectively), while sensitivity was similar to DLCO and higher than FVC (94.4%, 94.3%, 84.2%, respectively).

Discussion

The present study was planned for investigation of the usability of thorax USG as an imaging method in ILD. The ultrasonographic results (CTA numbers) of healthy individuals, and patients diagnosed with ILD were statistically significantly different. The mean number of CTA in healthy individuals was 25, and the mean number of CTA in ILD patients was 68 ($P < 0.05$). Ultrasonographic results, and HRCT, and PFT-DLCO results in ILDs were found correlated. The number of CTA increased as the HRCT scores of patients increased, and FVC-DLCO values decreased. The sensitivity (94%) and specificity (97%) of USG were found high for the diagnosis of the disease.

The importance of thoracic USG that is mainly used in the direct imaging of the pleural effusion, and peripherally located and pleural based masses of lung,

and the indirect imaging based on the analysis of the artefacts have been increasing. Diseases which involve the pulmonary parenchyma such as pulmonary edema or ILD may be evaluated owing to CTA-which is a reverberation artefact-detected in thoracic USG.^[13,14] Lichtenstein *et al.*^[15] first demonstrated in 1997 using the USG that CTA numbers increased in patients who developed diffuse interstitial fibrosis.

The pulmonary interstitium starts to reflect back the sound waves sent by the USG with the thickening of interlobular septas (ILS) with fluid as in the example of pulmonary edema, or with the thickening due to the accumulation of collagen tissue as in the example of ILD. CTAs are formed as a consequence of the infiltration of inflammatory cells of the thickened ILS or pulmonary interstitium.^[16] Sayed *et al.*^[17] in their study, investigating the USG results in ILD detected CTAs in 31 (73.8%) patients out of 42, and the most prevalent artefact type in ILD was reported to be the CTA artefact (B line artefact). The mean number of CTA in our study in patients with ILD was 68.3 ± 16.2 ; however, the mean number of CTA in the control group was 25 ± 6.4 ($P < 0.001$). Researchers in many studies proven the significant increase of CTA numbers in the presence of symptoms compatible with ILD.^[18,19] In this regard, the outcomes of our study were compatible with the literature.

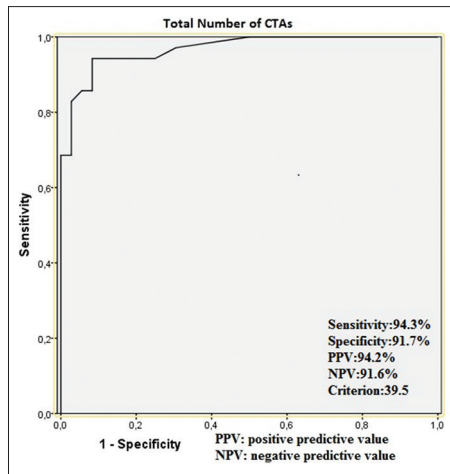


Figure 7: The curve demonstrating the optimal comet tail artifact cut-off value for DLCO in diagnosis of patients with ultrasonographic-spirometric interstitial lung disease (Interstitium was accepted as affected in case that DLCO % value was 80 or below 80)

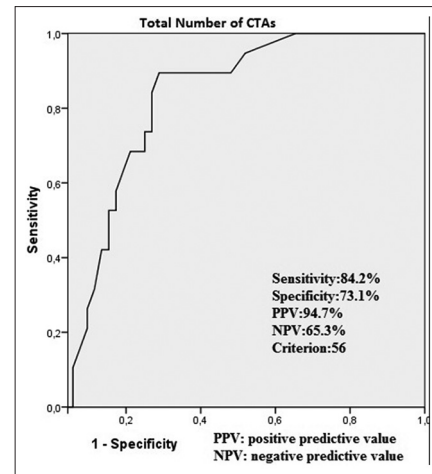


Figure 8: The curve demonstrating the optimal comet tail artifact cut-off value for forced vital capacity in diagnosis of patients with ultrasonographic-spirometric interstitial lung disease (Interstitium was accepted as affected in case that forced vital capacity % value was 80 or below 80)

Table 4: Number of comet tail artifacts detected on the anatomic lines in patients with interstitial lung diseases and in the control group

Anatomic line	ILD group (n=36)	Control group (n=35)	P
Right linea paravertebralis, mean±SD	6.6±2.7	1.34±0.8	<0.001
Right lineascapularis, mean±SD	7±2.3	2±0.8	<0.001
Right lineaaxillaris posterior, mean±SD	7.9±2.5	2.9±1.1	<0.001
Right lineaaxillaris media, mean±SD	7.1±2.4	2.9±1	<0.001
Right lineaaxillaris anterior, mean±SD	6.9±2.4	2.2±1.1	<0.001
Left linea paravertebralis, mean±SD	5.6±2.2	1.3±0.7	<0.001
Left lineascapularis, mean±SD	7.4±2.8	1.9±0.9	<0.001
Left lineaaxillaris posterior, mean±SD	7±2.3	2.4±1.1	<0.001
Left lineaaxillaris media, mean±SD	6.5±2.2	2.3±1	<0.001
Left lineaaxillaris anterior, mean±SD	6.1±2.4	1.9±0.9	<0.001
Mean number of CTAs, mean±SD	68.3±16.2	25±6.4	<0.001

CTAs: Comet tail artifact, SD: Standard deviation, ILD: Interstitial lung diseases

The most frequently used tests in the functional evaluation of the ILDs are the PFT-DLCO tests. The affected pulmonary parenchyma and the fibrosis symptoms in ILDs cause a decrease in the lung capacity. The decrease manifests with the decrease of FVC in simple spirometric tests.^[20] One another spirometric functional method in the evaluation of diseases such as ILD which affect the interstitium, and alveolar-capillary membrane of the lung is the DLCO test. Decrease of

DLCO may be detected in the early stages of interstitial lung disease which demonstrates the superiority of DLCO tests compared with the simple spirometric tests (FVC).^[21,22] The PFT-DLCO values in ILD group was found statistically highly significantly lower compared with the control group in our study ($P < 0.001$). In addition, there was a negative correlation between FVC, and DLCO parameters, with the number of CTAs. The number of CTAs increased as the FVC, and DLCO values of the patients decreased. The association between the number of CTA, and PFT-DLCO in the thoracic USG was proven in various studies. Gargani *et al.*^[23] detected a negative correlation between the CTA, and DLCO in patients diagnosed with systemic sclerosis ($r: -0.6; P < 0.05$). Similarly, Tardella *et al.*^[24] demonstrated the correlation between the numbers of CTA, and DLCO in ILD patients due to collagen tissue disease. Hasan and Makhoul^[25] in a recently published study detected the association in the distance between CTAs, and PFT-DLCO in 61 ILD patients majority of which consisting of IPF, and detected the negative correlation values as ($r: -0.848; P < 0.001$) for FVC%, and as ($r: -0.817; P < 0.001$) for DLCO. The correlation between the PFT-DLCO results, and USG results in ILD patients detected in the present study, and in other studies suggested that thorax USG may be beneficial in the evaluation of the ILD.

An imaging method of HRCT, which was specifically developed for the evaluation of the lung parenchyma, has almost become a standard imaging method in all ILDs.^[26] The most frequent HRCT findings in ILDs may be counted as the ground glass densities, reticular appearance, interseptal thickenings, nodules, cystic formations, traction bronchiectasies, and honeycomb appearance. The initial radiologic finding of the most of the ILS resulting with fibrosis was similar.^[27,28] The

healthy parenchyma of lung does not reflect back the sound waves sent by USG due to its content of air. However, some of the sound waves are reflected back, and this is described as CTA on the monitor in cases of the accumulation of collagen tissue in the lung interstitium, and associated with the interlobular septal thickening as observed in ILD.^[17] The USG findings (CTA numbers) of patients whose HRCT findings suggested ILD were found statistically significantly different in almost all the studies performed for the evaluation of lung parenchyma using the USG in ILDs. Barskova *et al.*^[29] in their study, investigating the importance of USG in the affected lung in systemic sclerosis found the CTA numbers statistically highly significantly increased in patients in whom ILD finding was detected in the HRCT ($P < 0.001$). In addition, the number of CTA of patients in whom ground glass was observed in HRCT was detected significantly higher compared with the CTA of patients in whom ground glass was not observed in HRCT in the same study ($P < 0.05$). Similarly, Çakir Edis *et al.*^[30] in their study investigating the efficacy of thorax USG in patients diagnosed with systemic sclerosis demonstrated that Warrick score, and CTA numbers were correlated. We found compatible results with the literature in our study. The total HRCT scores that are the collection of severity, and extension scores of HRCT of the patients, and CTA numbers were found correlated ($P: 0.01$, $r: 0.426$). In addition, the CTA numbers of the ILD patients that were classified in moderate and severe degree in accordance with the HRCT score was found statistically significantly different than each other. However, the CTA numbers of the patients in severe ILD group was found 74.7, the number was 61.8 in patients with moderate degree ILD ($P: 0.023$). The significant increase of CTA numbers in the presence of findings compatible with ILD in HRCT was proven in various studies.^[18,31,32]

We planned the present study for investigating the usability of USG which is an inexpensive, easily accessible, and repeatable imaging method which does not require exposure to radiation for the patient, and physician in ILD. The results of the present study demonstrated that the USG was compatible with the other diagnostic methods of ILD (HRCT-PFT-DLCO). The diagnostic sensitivity of USG in ILD was higher with 94.4% sensitivity, and with specificity of 97.1%. Considering the very high sensitivity, we suggest based on the results of this study that USG may be used as a screening tool in ILD.

Our study has some limitations. The most important limitation was that the variability both in intra observer, and inter observers was not measured in the evaluation of HRCT, and in the detection of thoracic USG, and CTA. One another limitation was that the study was conducted with relatively small number of patients, and reflected

the single-center experience. Therefore, the results cannot be interpreted for the general population. In addition, we believe that there were some parts about the disease specificity of USG that have not yet been fully clarified. We suggest that there is a need for more comprehensive studies investigating the number, and structure of CTA detected inground glass density, and of CTA detected in honeycomb appearance or whether USG showed earlier findings than HRCT, and DLCO.

Conclusion

As a result, interpreting the results of this study, it should be kept in mind that CTAs detected by thoracic USG can sometimes be seen in normal lung parenchyma (≤ 3). Therefore, we emphasise that in screening of ILD, USG findings should be supported by other diagnostic tools (clinical, radiological, and spirometric findings).

Acknowledgment

We would like to thank Dr. İlker Akine for the illustrations.

Financial support and sponsorship

Nil.

Conflicts of interest

There are no conflicts of interest.

References

1. Antoniou KM, Margaritopoulos GA, Tomassetti S, Bonella F, Costabel U, Poletti V. Interstitial lung disease. *Eur Respir Rev* 2014;23:40-54.
2. Keogh BA, Crystal RC. Clinical significance of pulmonary function tests. Pulmonary function testing in interstitial lung disease, what does it tell us? *Chest* 1980;78:856-65.
3. Leslie KO. My approach to interstitial lung disease using clinical, radiological and histopathological patterns. *J Clin Pathol* 2009;62:387-401.
4. Smargiassi A, Inchingolo R, Soldati G, Copetti R, Marchetti G, Zonforlin A, *et al.* The role of chest ultrasonography in the management of respiratory diseases: Document 2. *Multidiscip Respir Med* 2013;8:55.
5. Soldati G, Inchingolo R, Smargiassi A, Sher S, Nenna R, Inchingolo CD, *et al.* *Ex vivo* lung sonography: Morphologic-ultrasound relationship. *Ultrasound Med Biol* 2012;38:1169-79.
6. Mallamaci F, Benedetto FA, Tripepi R, Rastelli S, Castellino P, Tripepi G, *et al.* Detection of pulmonary congestion by chest ultrasound in dialysis patients. *JACC Cardiovasc Imaging* 2010;3:586-94.
7. Volpicelli G, Elbarbary M, Blaivas M, Lichtenstein DA, Mathis G, Kirkpatrick AW, *et al.* International evidence-based recommendations for point-of-care lung ultrasound. *Intensive Care Med* 2012;38:577-91.
8. Koenig SJ, Narasimhan M, Mayo PH. Thoracic ultrasonography for the pulmonary specialist. *Chest* 2011;140:1332-41.
9. Miller MR, Hankinson J, Brusasco V, Burgos F, Casaburi R, Coates A, *et al.* "ATS/ERS task force standardisation of lung function testing" Edited by V. Brusasco, R. Crapo and G. Viegi

- Number 2 in this Series Standardisation of spirometry. *Eur Respir J* 2005;26:319-38.
10. Standardization of Spirometry, 1994 Update. American Thoracic Society. *Am J Respir Crit Care Med* 1995;152:1107-36.
 11. Oda K, Ishimoto H, Yatera K, Naito K, Ogoshi T, Yamasaki K, *et al.* High-resolution CT scoring system-based grading scale predicts the clinical outcomes in patients with idiopathic pulmonary fibrosis. *Respir Res* 2014;15:10.
 12. Warrick JH, Bhalla M, Schabel SI, Silver RM. High resolution computed tomography in early scleroderma lung disease. *J Rheumatol* 1991;18:1520-8.
 13. Buda N, Piskunowicz M, Porzezińska M, Kosiak W, Zdrojewski Z. Lung ultrasonography in the evaluation of interstitial lung disease in systemic connective tissue diseases: Criteria and severity of pulmonary fibrosis-Analysis of 52 patients. *Ultraschall Med* 2016;37:379-85.
 14. Dietrich CF, Mathis G, Blaiwas M, Volpicelli G, Seibel A, Wastl D, *et al.* Lung B-line artefacts and their use. *J Thorac Dis* 2016; 8: 1356-65.
 15. Lichtenstein D, Mézière G, Biderman P, Gepner A, Barré O. The comet-tail artifact. An ultrasound sign of alveolar-interstitial syndrome. *Am J Respir Crit Care Med* 1997;156:1640-6.
 16. Agricola E, Bove T, Oppizzi M, Marino G, Zangrillo A, Margonato A, *et al.* "Ultrasound comet-tail images": A marker of pulmonary edema: A comparative study with wedge pressure and extravascular lung water. *Chest* 2005;127:1690-5.
 17. Sayed SS, Agmy GM, Said AF, Kasem AH. Assessment of transthoracic sonography in patients with interstitial lung diseases. *Egypt J Bronchol* 2016;10: 105-12.
 18. Sperandeo M, Varriale A, Sperandeo G, Filabozzi P, Piattelli ML, Carnevale V, *et al.* Transthoracic ultrasound in the evaluation of pulmonary fibrosis: Our experience. *Ultrasound Med Biol* 2009;35:723-9.
 19. Doveri M, Frassi F, Consensi A, Vesprini E, Gargani L, Tafuri M, *et al.* Ultrasound lung comets: New echographic sign of lung interstitial fibrosis in systemic sclerosis. *Reumatismo* 2008;60:180-4.
 20. Chetta A, Marangio E, Olivieri D. Pulmonary function testing in interstitial lung diseases. *Respiration* 2004;71:209-13.
 21. Hanson D, Winterbauer RH, Kirtland SH, Wu R. Changes in pulmonary function test results after 1 year of therapy as predictors of survival in patients with idiopathic pulmonary fibrosis. *Chest* 1995;108:305-10.
 22. Tabak L. Respiratory Function Tests in Parenchymal Diseases. In: Testleri SF, Saryal S, Ulubay G, editors. Ankara: Aves Yayıncılık; 2012. p. 185-90.
 23. Gargani L, Doveri M, D'Errico L, Frassi F, Bazzichi ML, Delle Sedie A, *et al.* Ultrasound lung comets in systemic sclerosis: A chest sonography hallmark of pulmonary interstitial fibrosis. *Rheumatology (Oxford)* 2009;48:1382-7.
 24. Tardella M, Gutierrez M, Salaffi F, Carotti M, Ariani A, Bertolazzi C, *et al.* Ultrasound in the assessment of pulmonary fibrosis in connective tissue disorders: Correlation with high-resolution computed tomography. *J Rheumatol* 2012;39:1641-7.
 25. Hasan AA, Makhlouf HA. B-lines: Transthoracic chest ultrasound signs useful in assessment of interstitial lung diseases. *Ann Thorac Med* 2014;9:99-103.
 26. Kanne JP. Interstitial lung disease (ILD): Imaging finding, and the role of imaging in evaluating the patient with known or suspected ILD. *Semin Roentgenol* 2010;45:3.
 27. Meyer KC. Diagnosis and management of interstitial lung disease. *Transl Respir Med* 2014;2:4.
 28. Hodnett PA, Naidich DP. Fibrosing interstitial lung disease. A practical high-resolution computed tomography-based approach to diagnosis and management and a review of the literature. *Am J Respir Crit Care Med* 2013;188:141-9.
 29. Barskova T, Gargani L, Guiducci S, Randone SB, Bruni C, Carnesecchi G, *et al.* Lung ultrasound for the screening of interstitial lung disease in very early systemic sclerosis. *Ann Rheum Dis* 2013;72:390-5.
 30. Çakir Edis E, Hatipoğlu ON, Pamuk ÖN, Mutlucan Eraslan R, Aktöz M, Tuncel SA. Effectiveness of thoracic ultrasonography in the evaluation of the severity of pulmonary involvement in patients with systemic sclerosis. *Arch Rheumatol* 2016;31:364-70.
 31. Targhetta R, Chavagneux R, Balmes P, Lemerre C, Mauboussin JM, Bourgeois JM, *et al.* Sonographic lung surface evaluation in pulmonary sarcoidosis: Preliminary results. *J Ultrasound Med* 1994;13:381-8.
 32. Bouhemad B, Zhang M, Lu Q, Rouby JJ. Clinical review: Bedside lung ultrasound in critical care practice. *Crit Care* 2007;11:205.