

Access this article online

Quick Response Code:



Website:

<https://eurasianjipulmonol.org>

DOI:

10.14744/ejp.2023.7005

A rare cause of interstitial lung disease: Niemann-Pick

Ayşegül Erinç, Neslihan Fener¹, Filiz Koşar

ORCID:

Ayşegül Erinç: 0000-0001-8822-7944

Neslihan Fener: 0000-0002-2171-5844

Filiz Koşar: 0000-0001-5707-2716

Abstract:

Niemann-Pick disease (NPD) is a rare lysosomal storage disease (LSD) with multisystemic involvement. The disease is heterogeneous and is classified into three subtypes. Types A and B result from deficient acid sphingomyelinase activity, leading to the accumulation of sphingomyelin. In contrast, Type C is a genetically distinct disease resulting from defective intracellular accumulation of cholesterol and glycosphingolipids. Type B is a less severe form characterized by pulmonary involvement, hepatosplenomegaly, and hyperlipidemia, with most patients living into adulthood. Storage diseases, rare causes of systemic organ involvement, should be considered in patients being evaluated for interstitial lung disease. Patients should be managed in a multidisciplinary manner. In this case report, we present a patient with a persistent cough for several months. Examinations revealed thrombocytopenia, hyperlipidemia, splenomegaly, and an alternative diagnosis for usual interstitial pneumonia. The patient underwent wedge resection of the upper and lower lobes of the left lung. Plasma chitotriosidase activity was elevated, beta-glucosidase activity was normal, leukocyte sphingomyelinase activity was low, and a homozygous sphingomyelin phosphodiesterase 1 (SMPD1) gene mutation was found. After evaluating all findings, the patient was diagnosed with Niemann-Pick Type B.

Keywords:

Interstitial lung disease, lysosomal storage disease, pediatric pulmonary disease

Department of
Pulmonology, Yedikule
Chest Disease and
Thoracic Surgery Training
and Research Hospital,
Istanbul, Türkiye,

¹Department of Pathology,
Yedikule Chest Disease
and Thoracic Surgery
Training and Research
Hospital, Istanbul, Türkiye

Address for correspondence:

Dr. Ayşegül Erinç,

Department of

Pulmonology, Yedikule

Chest Disease and

Thoracic Surgery Training

and Research Hospital,

Istanbul, Türkiye.

E-mail:

draysgul@hotmail.com

Received: 31-07-2023**Revised:** 07-09-2023**Accepted:** 30-10-2023**Published:** 21-11-2023

Introduction

Niemann-Pick disease (NPD) is a rare lysosomal storage disorder (LSD) inherited in an autosomal recessive pattern. The disease is divided into three different subgroups. Types A and B are characterized by a deficiency in acid sphingomyelinase activity due to a mu-

tation in the sphingomyelin phosphodiesterase 1 gene (SMPD1). This deficiency leads to the accumulation of lipid-rich macrophages (Niemann-Pick cells) in several tissues, particularly in the liver and spleen. Type A, a neurological condition, can be lethal in infancy. In contrast, the majority of individuals with Type B Niemann-Pick disease, a less severe vari-

How to cite this article: Erinç A, Fener N, Koşar F. A rare cause of interstitial lung disease: Niemann-Pick. *Eurasian J Pulmonol* 2024;26:140-143.

This is an open access journal, and articles are distributed under the terms of the Creative Commons Attribution-NonCommercial-ShareAlike 4.0 License, which allows others to remix, tweak, and build upon the work non-commercially, as long as appropriate credit is given and the new creations are licensed under the identical terms.

For reprints contact: kare@karepb.com

ant, live into adulthood. This type is characterized by hepatosplenomegaly, hyperlipidemia, pulmonary involvement, and milder neurological symptoms. Lipid deposition is slow yet progressive, leading to interstitial lung disease with the accumulation of foamy macrophages in the alveoli.^[1] Niemann-Pick disease Type C, resulting from mutations in the Niemann-Pick disease, type C1 (NPC1) and Niemann-Pick disease, type C2 (NPC2) genes, is a complex disorder involving lipid accumulation, which manifests clinically as neurological dysfunction. Although all three forms of Niemann-Pick disease involve the lungs, Type B exhibits this more frequently. Patients' clinical presentation can range from asymptomatic to severe respiratory failure. Niemann-Pick cells accumulate in the alveolar septa, bronchial walls, and pleura, leading to the progression of respiratory tract disease.

Case Report

A 52-year-old female patient was admitted to our clinic with a cough that had persisted for several months. She had a history of hyperlipidemia and had been evaluated for hepatosplenomegaly few years ago, but no diagnosis was made. The patient, an active smoker with a history of 30 pack-years, presented with no findings other than splenomegaly during the physical examination. Laboratory tests revealed low platelet counts ($94 \times 10^3/\text{mm}^3$) and high triglyceride and low-density lipoprotein (LDL) cholesterol values (325 mg/dL and 169 mg/dL, respectively), while other values were normal. The patient's chest X-ray showed reticular patterns in both lung bases and calcified nodular opacity in the middle zone of the left lung [Fig. 1a]. Computed tomography examination revealed interlobular septal thickening, honeycomb-like fibrotic changes, and a more pronounced diffuse reticular pattern in the basal segments of both lungs. Findings were consistent with an alternative diagnosis for usual interstitial pneumonia [Fig. 1b]. The results of the pulmonary function test were as follows: forced expiratory volume in 1 second (FEV_1): 2.28 L (114%), forced vital capacity (FVC): 2.82 L (119), FEV_1/FVC : 80.76% (101%), and diffusing capacity of the lungs for carbon monoxide (DLCO): 9.08 mL/min/mmHg (51%). The connective tissue markers were normal. The patient was scheduled for an open lung biopsy. After consultation with thoracic surgery, it was decided to perform a wedge resection of the up-

per and lower lobes of the left lung. In the histopathological examination, a buildup of macrophages with foamy cytoplasm was observed, filling the alveolar spaces uniformly without affecting the alveolar septal structure [Fig. 2]. As a result of collaboration with a pathologist experienced in thoracic pathologies, a research project was established regarding storage diseases in the patient. Further testing of the patient for storage diseases was planned in light of the clinical and histopathological findings. In the bone marrow biopsy, hypercellular bone marrow containing histiocyte cells with microvesicular cytoplasm in the form of large patches was seen. With this finding, glycogen storage diseases were excluded. The patient's genetic tests for lysosomal storage diseases revealed high plasma chitotriosidase enzyme activity, normal beta-glucosidase activity, and low leukocyte sphingomyelinase enzyme activity. A homozygous SMPD1 gene mutation was discovered after genetic testing. After evaluating all findings together, the patient was diagnosed with Niemann-Pick Type B.

Discussion

Herein, we briefly describe a patient with NPD Type B. Our case had lung involvement with respiratory symptoms. NPD Type B is a heterogeneous disease with multiple possible presentations. Respiratory symptoms, when present, are usually mild, including recurrent cough, exertional dyspnea, and recurrent infections. However, rapidly fatal and progressive lung disease has also been reported.^[2] The management of all forms of NPD is supportive. For patients with pulmonary involvement, oxygen and physical therapy can be provided. Following the diagnosis, it is recommended to monitor a child's growth, weight, bleeding management, pulmonary function tests, liver enzyme levels, lipid profile, chest X-ray, and bone development. Bone marrow and lung transplants have also been performed, but they are uncommon and have poor success rates.^[3,4] Whole lung lavage is a high-risk procedure with transient benefits; however, it has been effective in a few cases.^[5] According to the literature, whole-lung lavage reduces surfactant impairment and alveolar filling caused by the presence of foamy cells, leading to substantial symptomatic and radiographic improvements.^[6] Although there is no effective treatment for Type B, gene therapies and enzyme replace-

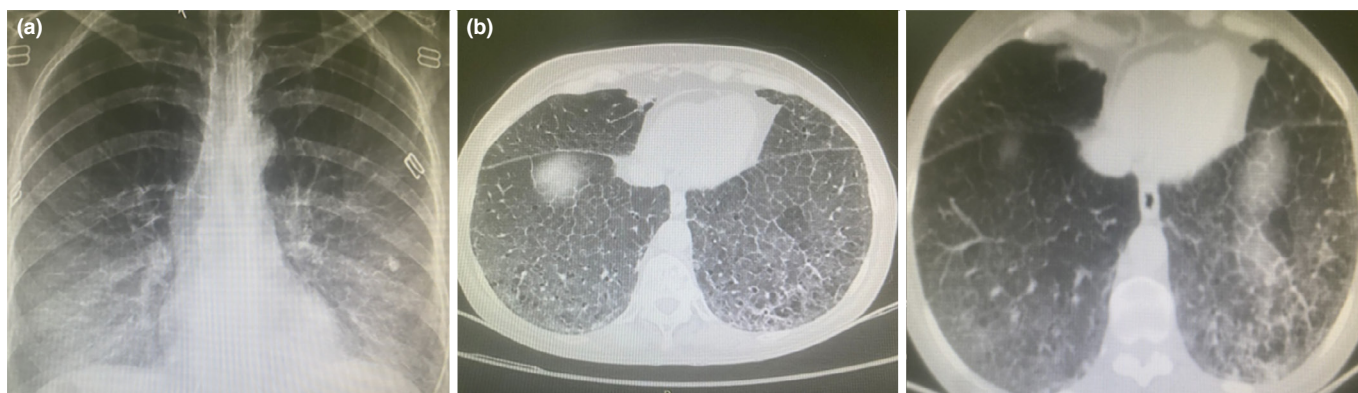


Figure 1: (a) Chest X-ray of patient. (b) Thorax computed tomography of patient

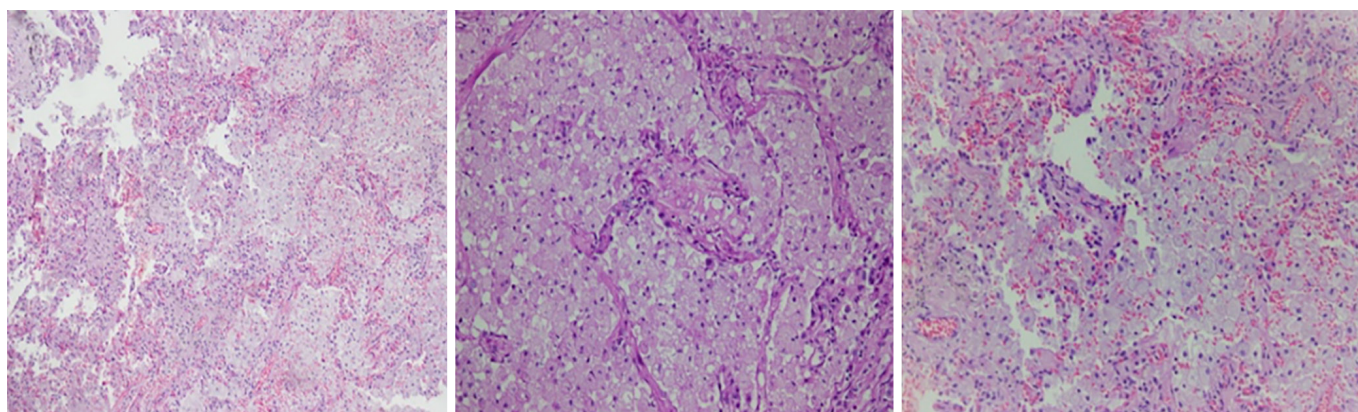


Figure 2: Macrophages with foamy cytoplasm in alveolar space 20×10 Hematoxylin eosin, Weak PAS positive staining 20×10 Hematoxylin eosin, Nieman-pick cells with cytoplasm vacuole cytoplasm 20×10 Hematoxylin eosin
PAS: Periodic acid schiff

ment therapy (olipudase alfa) have been the focus of clinical trials. Recombinant human acid sphingomyelinase, or olipudase alfa, is a potential enzyme replacement therapy for treating the non-neurologic manifestations of acid sphingomyelinase deficiency.^[7] A lung biopsy should raise the possibility of a storage disease in a patient with interstitial lung disease who also has hepatosplenomegaly, hypercholesterolemia, and thrombocytopenia, in addition to current clinical and laboratory findings. The treatment options should then be assessed by carrying out the necessary tests in accordance with this suspicion. In light of all the research, we decided to follow up with our patient by conducting annual chest X-rays and biannual respiratory function tests. As in our case, it is important to keep in mind that storage diseases are rare causes in patients with systemic organ involvement who are being evaluated for interstitial lung disease. Patients with these conditions should be managed in a multidisciplinary manner.

Informed Consent

Written informed consent was obtained from the patient for the publication of the case report and the accompanying images.

Conflicts of interest

There are no conflicts of interest.

Financial support and sponsorship

Nil.

Peer-review

Externally peer-reviewed.

Authorship Contributions

Concept – A.E., F.K., N.F.; Design – A.E., F.K., N.F.; Supervision – A.E., F.K., N.F.; Materials – A.E., F.K.; Data collection &/or processing – A.E.; Analysis and/or interpretation – A.E., F.K.; Literature search – A.E., F.K., N.F.; Writing – A.E., F.K.; Critical review – A.E., F.K.

References

1. Wasserstein MP, Schuchman EH. Acid Sphingomyelinase Deficiency. In: Adam MP, Feldman J, Mirzaa GM, Pagon RA, Wallace SE, Bean LJH, Gripp KW, Amemiya A, editors. GeneReviews®. Seattle (WA):University of Washington,Seattle;1993-2023.
2. Guillemot N, Troadec C, de Villemeur TB, Clément A, Fauroux B. Lung disease in Niemann-Pick disease. *Pediatr Pulmonol* 2007;42(12):1207–14. [CrossRef]
3. Schuchman EH, Wasserstein MP. Types A and B Niemann-Pick disease. *Best Pract Res Clin Endocrinol Metab* 2015;29(2):237–47.
4. Capron T, Trigui Y, Gautier C, Puech B, Chanez P, Reynaud-Gaubert M. Respiratory impairment in Niemann-Pick B disease: Two case reports and review for the pulmonologist. *Respir Med Res* 2019;76:13–8. [CrossRef]
5. Uyan ZS, Karadağ B, Ersu R, Kiyancı G, Kotiloğlu E, Sirvancı S, et al. Early pulmonary involvement in Niemann-Pick type B disease: lung lavage is not useful. *Pediatr Pulmonol* 2005;40(2):169–72. [CrossRef]
6. Iaselli F, Rea G, Cappabianca S, Fabozzi G, Montemarano M, Vitale C, et al. Adult-onset pulmonary involvement in Niemann-Pick disease type B. *Monaldi Arch Chest Dis* 2011;75(4):235–40. [CrossRef]
7. FDA approves first treatment for acid sphingomyelinase deficiency, a rare genetic disease. Available at: http://www.accessdata.fda.gov/drugsatfda_docs/applletter/2022/761261Orig1s000ltr.pdf Accessed Oct 19, 2022.