

Access this article online

Quick Response Code:

Website:
<https://eurasianj pulmonol.org>DOI:
10.14744/ejp.2023.1106

Videobronchoscopic image of a ruptured hydatid cyst presenting as a cavitory lung lesion

Nurdan Şimşek Veske¹, Ekrem Cengiz Seyhan¹, Ali Murat Akçıl², Neslihan Fener³

ORCID:

Nurdan Şimşek Veske: 0000-0001-6817-3416

Ekrem Cengiz Seyhan: 0000-0001-6639-2797

Ali Murat Akçıl: 0000-0002-1855-6053

Neslihan Fener: 0000-0002-2171-5844

Abstract:

Hydatid cyst (HC) is a zoonotic parasitic disease caused by the organism *Echinococcus granulosus*. Türkiye is among the countries where this disease is endemic. Lungs are the most common site of involvement after the liver. Diagnosis may not be easy when cysts are complicated. A 40-year-old female patient had complaints of shortness of breath and chest pain for one-month, as well as a new onset of fever. She was referred to our center because her complaints persisted despite antibiotic treatment. Her medical, family histories, and lifestyle habits were unremarkable. The physical examination was normal. Routine laboratory analyses, including a hemogram and serum biochemistry, were within normal ranges. However, C-Reactive Protein (CRP) levels were elevated. A cavitory lesion with an irregular inner wall was observed on the chest radiograph. The patient was unable to expectorate sputum. With regard to the preliminary diagnosis of tuberculosis, abscess, and malignancy, a fiberoptic bronchoscopy was performed. An off-white, folded, paper-like lesion was observed in a subsegment of the anterior segment of the right upper lobe bronchus. A biopsy was taken and it was seen that the lesion continued with its distal part. The pathology results indicated a germinal membrane belonging to a HC. We present the patient's endobronchial appearance, which is distinctive for ruptured HC. We believe that existing videobronchoscopic images will guide bronchoscopists. This case highlights the importance of considering a HC in the differential diagnosis of cavitory lesions.

Keywords:

Cavitory lesion, hydatid cyst, videobronchoscopic images

Introduction

Hydatid cyst (HC) is a zoonotic parasitic disease caused by the organism *Echinococcus granulosus*. Cysts can be located in any part of the body, but they most

commonly involve the liver and the lungs.

[1] Clinical manifestations are influenced by the cyst's location and size. HCs are usually symptomatic and often identified following complications like perforation and superinfection. This report presents a

How to cite this article: Şimşek Veske N, Seyhan EC, Akçıl AM, Fener N. Videobronchoscopic image of a ruptured hydatid cyst presenting as a cavitory lung lesion. Eurasian J Pulmonol 0000;00:000-00.

This is an open access journal, and articles are distributed under the terms of the Creative Commons Attribution-NonCommercial-ShareAlike 4.0 License, which allows others to remix, tweak, and build upon the work non-commercially, as long as appropriate credit is given and the new creations are licensed under the identical terms.

For reprints contact: kare@karepb.com

¹Department of Chest Disease, University of Health Sciences, Yedikule Chest Diseases and Thoracic Surgery Training and Research Hospital, İstanbul, Türkiye,

²Department of Chest Surgery, University of Health Sciences, Yedikule Chest Diseases and Thoracic Surgery Training and Research Hospital, İstanbul, Türkiye,

³Department of Pathology, University of Health Sciences, Yedikule Chest Diseases and Thoracic Surgery Training and Research Hospital, İstanbul, Türkiye

Address for correspondence:

Dr. Nurdan Şimşek Veske, Department of Chest Disease, University of Health Sciences Yedikule Chest Diseases and Thoracic Surgery Training and Research Hospital, İstanbul, Türkiye.
E-mail: nrdnsimsek@gmail.com

Received: 02-12-2023
Accepted: 13-01-2024
Published: 08-02-2024

case, supported by videobronchoscopic images, of a patient who underwent fiberoptic bronchoscopy (FOB) for a persistent cavitory lesion in the in the anterior segment of right upper lobe, unresponsive to antibiotics, and was subsequently diagnosed with a HC.

Case Report

A 40-year-old female patient was referred to our hospital for further examination following a one-month history of right chest pain, shortness of breath, and a newly developed fever. Her medical, family histories, and lifestyle habits were unremarkable. The physical examination was normal. Routine laboratory analyses, including a hemogram and serum biochemistry, were within normal ranges. However, C-Reactive Protein (CRP) levels were elevated. The patient had received ampicillin sulbactam (2×1 g) and cefuroxime axetil (2×500 mg) orally before admission to our clinic. A chest radiography revealed a cavitory lesion in the right upper zone [Fig. 1]. A computed tomography (CT) of the thorax revealed a cavitory mass lesion in the anterior segment of right upper lobe, measuring 37×36 mm [Fig. 2]. The patient was unable to expectorate sputum. With preliminary diagnoses of tuberculosis, abscess, and malignancy, a fiberoptic bronchoscopy was performed. An off-white, folded, paper-like lesion was observed in a subsegment of the anterior segment of the right upper lobe bronchus [Fig. 3]. When removal was attempted with biopsy forceps, it was observed that the lesion was continuous with the distal part. Given that the biopsy materials resembled onion skins, they were suspected to be the membrane of a HC. Lavage was collected, and the procedure was terminated (Appendix 1). Concurrently, the patient was tested for a HC using the indirect hemagglutination (IHA) test. Further anamnesis revealed that the patient, although not reporting any contact with dogs or sheep, had a history of frequent travel to the southeastern Anatolia region, where HCs are endemic. The lavage acid-fast bacillus (AFB) and polymerase chain reaction (PCR) results were negative. The pathology results indicated a germinal membrane belonging to a HC [Fig. 4]. The IHA test for HC was positive with a titer of 1/2560. The patient referred for surgery. A right thoracotomy, cystotomy, and capitonnage were performed, and the patient was discharged without any postoperative complications.

Discussion

Türkiye is among the countries where HC is endemic. Lung HCs are generally solitary, well-circumscribed, homogeneous, round or oval shaped, and usually occur at the lung bases.^[2,3]

Cysts located in the lung periphery are mostly asymptomatic, whereas symptoms are more prominent in centrally located large cysts due to the compression of adjacent organs. Pulmonary rupture of the cyst can lead to cough, dyspnea, fever, hemoptysis, flank pain, chest pain, and secondary pneumonia due to pressure on adjacent bronchi.^[4] Lung abscess due to post-rupture secondary infection, as well as hydropneumothorax or empyema due to intrapleural rupture, may occur. Rarely, massive hemoptysis may be observed. Rock water and membrane expectoration (Hydatoptosis), seen in 2–9% of lung HC cases, are pathognomonic findings of the disease and occur when the cyst ruptures into the bronchus. In our case, the patient did not describe

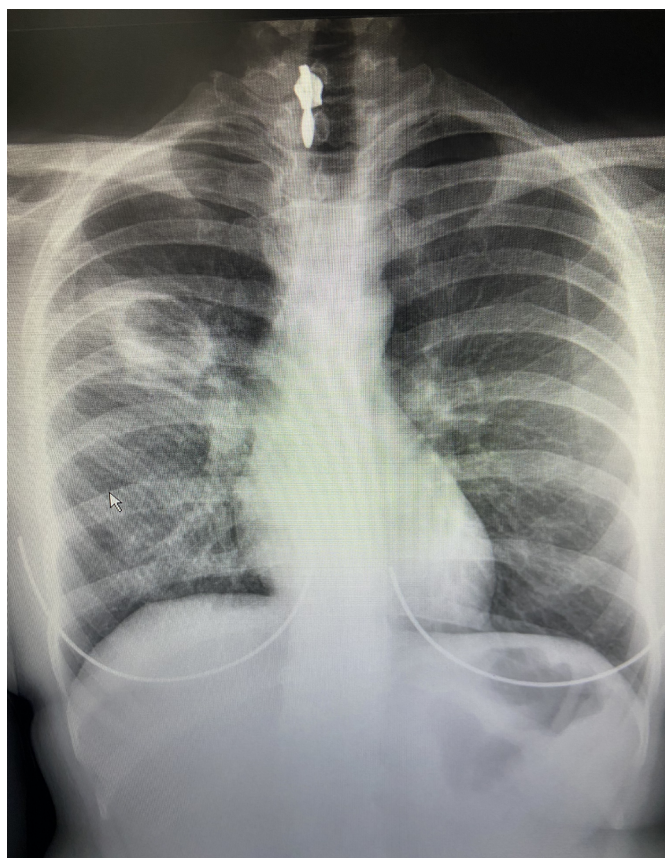


Figure 1: A cavitory lesion with an irregular inner wall in the right upper zone as shown in posteroanterior (PA) chest radiography

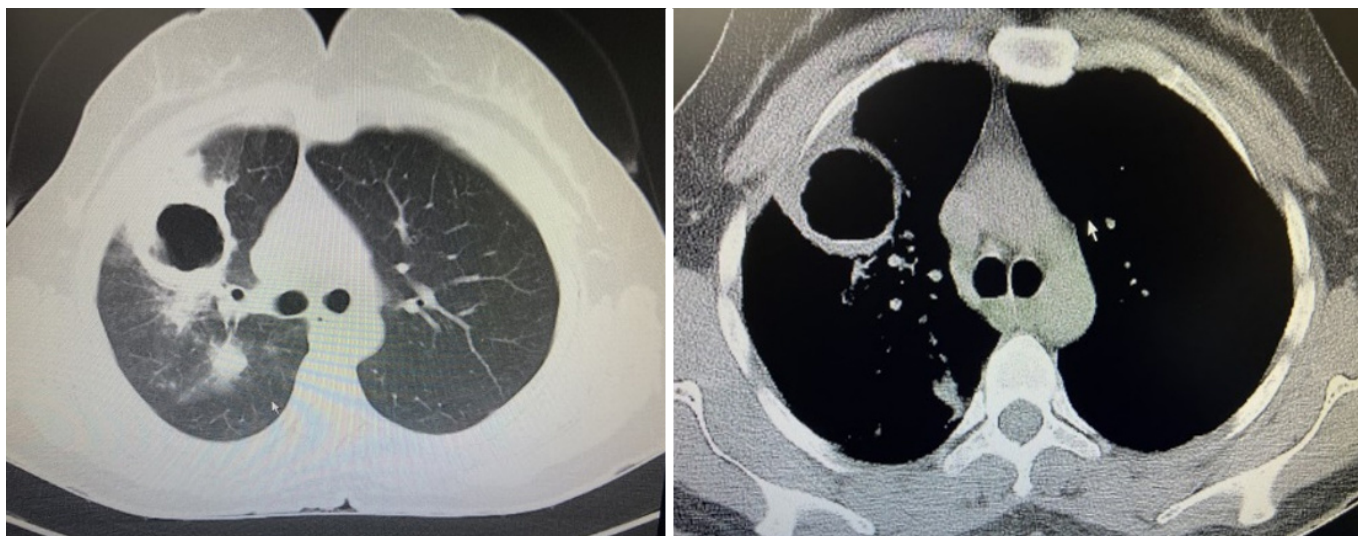


Figure 2: A cavitary mass lesion measuring 37×36 mm, located in the anterior segment of the right upper lobe

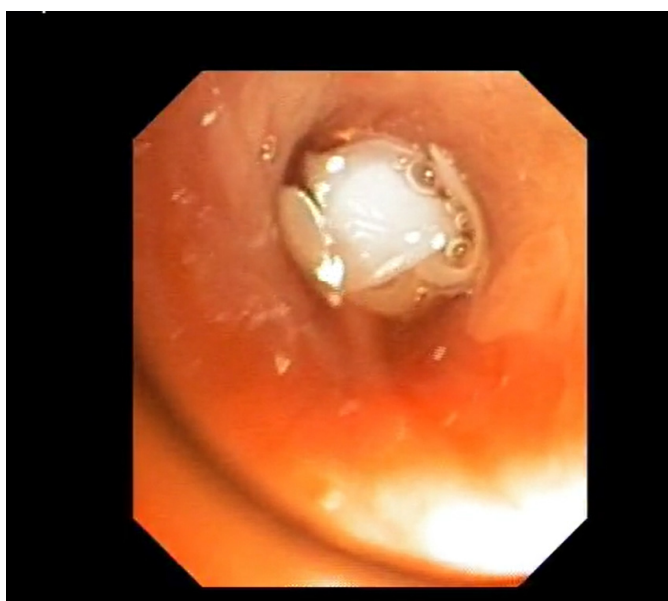

Figure 3: Off-white endobronchial lesion obstructing a subsegment of the bronchus in the anterior segment of the right upper lobe

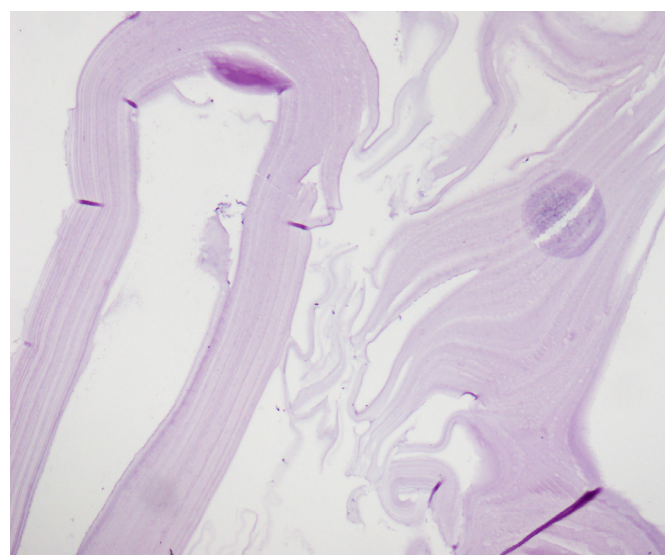


Figure 4: Eosinophilic germinal membrane showing 4x10 Hematoxylin and Eosin (HE) lamination

such a history in the anamnesis. Clinical and radiological findings were not typical for HC. The diagnosis of HC can be easily made through appropriate serology, direct radiography, or CT images, and FOB has no place in the diagnosis. However, it can be performed in atypical presentations, where the differential diagnosis includes pulmonary tuberculosis, lung abscess, necrotizing pneumonia, and malignancy. The presence of an endobronchial lesion on existing FOB images may also be confused with foreign body aspirations in cases with cavitary lesions and abscess formation

on CT sections. Although bronchoscopy has complication risks such as cyst rupture and anaphylaxis, we believe that it can be performed safely in experienced centers to make a differential diagnosis in patients whose definitive diagnosis cannot be made.

The bronchoscopic appearance of pulmonary HC had previously been described as whitish, folded, and laminated membranes.^[5,6] In the bronchoscopic examination of our patient, cream-colored membranous material was observed, and histological examination confirmed it as a fragment of a hydatid cyst.

Serological testing for anti-hydatid antibodies may assist in diagnosis, but it has a much lower sensitivity for pulmonary HC compared to liver cysts. Therefore, negative serology cannot rule out hydatid disease.

Whether the cyst is symptomatic or asymptomatic, surgical excision, aimed at preserving as much lung parenchyma as possible, is the primary treatment method. Medical treatment can be employed for patients with multiple cysts or for those deemed inoperable due to accompanying comorbidities.

In conclusion, diagnosing complicated pulmonary HCs may be difficult. Pulmonary HC should be considered in the differential diagnosis in cases like our patient, who has a history of frequent travel to endemic regions, and in instances where cystic-cavitary infiltration is observed on chest imaging, along with a membranous endobronchial lesion on FOB.

Appendix video file

Endobronchial view of hydatid cyst membrane

Informed Consent

Written informed consent was obtained from the patient for the publication of the case report and the accompanying images.

Conflicts of interest

There are no conflicts of interest.

Financial support and sponsorship

Nil.

Peer-review

Externally peer-reviewed.

Authorship Contributions

Concept – N.Ş.V., A.M.A.; Design – N.Ş.V.; Supervision – E.C.S., N.F.; Funding – N.Ş.V.; Materials – N.Ş.V.; Data collection &/or processing – N.Ş.V., A.M.A.; Analysis and/or interpretation – N.F.; Literature search – N.Ş.V., A.M.A.; Writing – N.Ş.V., E.C.S.; Critical review – E.C.S., N.F.

References

1. Basavana GH, Siddesh G, Jayaraj BS, Krishnan MG. Ruptured hydatid cyst of lung. *J Assoc Physicians India* 2007;55:141–5.
2. Anantharaman M. Pulmonary hydatidosis in India: An overview. *Lung India*. 1983;1:123–7.
3. Kulpati DD, Hagroo AA, Talukdar CK, Ray D. Hydatid disease of the lung. *Indian J Chest Dis* 1974;16(4):406–10.
4. Özdemir A, Bozdemir ŞE, Akbiyik D, Daar G, Korkut S, Korkmaz L, et al. Anaphylaxis due to ruptured pulmonary hydatid cyst in a 13-year-old boy. *Asia Pac Allergy* 2015;5(2):128–31.
5. Saygi A, Oztek I, Güder M, Süngün F, Arman B. Value of fiberoptic bronchoscopy in the diagnosis of complicated pulmonary unilocular cystic hydatidosis. *Eur Respir J* 1997;10(4):811–4.
6. Yilmaz A, Tuncer LY, Damadoglu E, Sulu E, Takir HB, Selvi UB. Pulmonary hydatid disease diagnosed by bronchoscopy: a report of three cases. *Respirology* 2009;14(1):141–3.