

Access this article online

Quick Response Code:

Website:
https://eurasianj pulmonol.orgDOI:
10.14744/ejp.2024.1107

Aspergillus flavus mediastinitis in an immunocompetent patient: Is treatment possible when the underlying risk factor cannot be reversed?

Derya Kaya¹, Meltem Işıkgöz Taşbakan¹, Mehmet Sezai Taşbakan², Pakize Çağlayan², Akın Çinkooğlu³, Mustafa Hikmet Özhan²

ORCID:

Derya Kaya: 0009-0000-6675-1198
Meltem Işıkgöz Taşbakan: 0000-0002-4689-720X
Mehmet Sezai Taşbakan: 0000-0003-4507-9851
Pakize Çağlayan: 0000-0002-0160-9200
Akın Çinkooğlu: 0000-0003-3396-3949
Mustafa Hikmet Özhan: 0000-0001-5535-7355

Abstract:

Aspergillus is a mold fungus frequently encountered in nature, notably in soil, boasting over 900 different species. The risk of infection primarily hinges on the host's immune status, with increased susceptibility in conditions of immune suppression from various causes. Although invasive aspergillosis can affect multiple organs, lung infections predominate. Mediastinitis related to *Aspergillus* is exceedingly rare. This article aims to discuss a case of *Aspergillus* mediastinitis in an immunocompetent individual, a rarity in itself. *Aspergillus* species are ubiquitous mold fungi found primarily in soil, with *Aspergillus fumigatus* being the leading cause of *Aspergillus* infections in humans. While invasive aspergillosis can affect various organs, lung infections are most common, particularly in immunocompromised individuals. Mediastinitis related to *Aspergillus* is exceedingly rare. This case report describes a rare instance of *Aspergillus* mediastinitis in a 51-year-old man with well-managed type 2 diabetes, hypertension, and a history of myocardial infarction. He presented with symptoms of cough, sputum, and back pain, and was initially investigated for pneumonia. Imaging revealed a large mediastinal mass, which led to a diagnosis of a mediastinal abscess. Despite initial broad-spectrum antibiotic treatment and surgical intervention, the patient's condition did not significantly improve. Further investigation revealed an *Aspergillus flavus* infection. The patient underwent prolonged antifungal therapy, including Amphotericin B and voriconazole, and additional interventions including bronchoscopy and stent placement. Despite partial regression of the mass and resolution of some symptoms, persistent fungal and bacterial infections were noted. This case highlights the complexity of diagnosing and treating *Aspergillus* mediastinitis, especially in immunocompetent individuals, and underscores the need for comprehensive diagnostic and therapeutic approaches.

Keywords:

Aspergillus flavus, immunocompetent patient, mediastinitis

How to cite this article: Kaya D, Işıkgöz Taşbakan M, Taşbakan MS, Çağlayan P, Çinkooğlu A, Özhan MH. *Aspergillus flavus* mediastinitis in an immunocompetent patient: Is treatment possible when the underlying risk factor cannot be reversed? Eurasian J Pulmonol 2024;26:214-219.

This is an open access journal, and articles are distributed under the terms of the Creative Commons Attribution-NonCommercial-ShareAlike 4.0 License, which allows others to remix, tweak, and build upon the work non-commercially, as long as appropriate credit is given and the new creations are licensed under the identical terms.

For reprints contact: kare@karepb.com



¹Department of Infectious Diseases and Clinical Microbiology, Ege University, İzmir, Türkiye,
²Department of Chest Diseases, Ege University, İzmir, Türkiye,
³Department of Radiology, Ege University, İzmir, Türkiye

Address for correspondence:

Dr. Meltem Işıkgöz Taşbakan,
Department of Infectious Diseases and Clinical Microbiology, Ege University, İzmir, Türkiye.
E-mail: tasbakan@yahoo.com

Received: 28-12-2023

Revised: 19-02-2024

Accepted: 23-03-2024

Published: 18-10-2024

Introduction

With over 900 species, *Aspergillus* is a mold fungus that is widespread in nature, particularly in soil. Beyond soil and plants, these fungi can be found in various environments including decayed organic matter, manure, construction sites, air/aerosols, and water systems. Only a small number of species cause infections in humans.^[1] The occurrence of infection is primarily determined by the host's immune status. The risk of fungal infection is particularly high in patients with conditions such as long-term neutropenia, advanced human immunodeficiency virus (HIV) infection, hereditary immunodeficiency, allogeneic hematopoietic stem cell and/or solid organ transplantation, extensive use of immunosuppressive drugs and antibiotics, as well as in cases of alcoholism, diabetes mellitus, and long-term steroid treatment. Underlying risk factors should be carefully evaluated in patients with recurrent culture positivity who do not respond to standard treatment. In rare instances, infections can also develop in patients without any identifiable risk factors.^[2-4]

While *Aspergillus fumigatus* is responsible for more than 90% of infections in humans, *Aspergillus flavus* accounts for 10% of invasive diseases, and *Aspergillus niger* and *Aspergillus terreus* each account for 2%.^[2,3] A definitive diagnosis often requires the growth of a culture from a sample taken from sterile tissue, although biopsies are not always possible. In such cases, radiological imaging and serum biomarkers such as galactomannan and beta-D glucan are useful diagnostic tools.^[5,6]

Lung infection is the most common manifestation, although invasive aspergillosis can involve various organs. Mediastinitis is rarely seen. There are documented cases of *Aspergillus* mediastinitis following cardiac surgeries. This article discusses a case of *Aspergillus* mediastinitis in an immunocompetent patient, a rare occurrence.

Case Report

A 51-year-old man with type 2 diabetes mellitus, hypertension, and a history of myocardial infarction presented at various clinics with complaints of cough, sputum, and back pain lasting for two months. He was initially investigated for pneumonia and subsequently referred to our hospital after mediastinal lymphadenopathy (LAP) was detected on chest imaging. In November

2022, he was admitted to the chest diseases clinic of our hospital. Computed tomography angiography (CTA) revealed a mass in the mediastinum. This mass filled the right and left lower paratracheal regions and the subcarinal region, extending to the right upper paratracheal and right hilar regions. It caused narrowing of the proximal parts of the carina and main bronchi due to anterior-superior compression [Fig. 1a]. The lobulated contour mass was continuous with right hilar and subcarinal lymphadenopathy. At the subcarinal level, where the beam hardening artefact caused by the contrast agent was minimally visible, the region of interest (ROI) circle was placed on the mass. The measured density (HU: Hounsfield Unit) corresponded to fluid content [Fig. 1b]. Additional computed tomography (CT) findings included pericardial effusion and gravity-dependent atelectasis in the lung [Fig. 1c].

A bronchoscopy was performed, and initial treatment with ceftriaxone 2×1 g intravenous (IV) and metronidazole 3×500 mg IV was administered following the collection of samples for microbiological cultures. The bronchoscopy revealed narrowing at the entrances of both main bronchi due to external compression, and purulent fluid was aspirated and sent for culture. Growth of *Acinetobacter pittii* and *Candida tropicalis* in the bacteriological and mycological cultures led to a switch in treatment to piperacillin/tazobactam 3×4.5 g IV and ciprofloxacin 2×500 mg orally. The pathology report stated: "Structures, which may be acellular foreign bodies, in which bile pigment can be distinguished in places on a ground consisting of fungal hyphae-spores, necrosis, polymorphic leukocyte population and metaplastic squamous cells." Given a preliminary diagnosis of an abscess, cyst, or teratoma, the patient was referred to thoracic surgery. The thoracic surgery team successfully drained the mediastinal abscess. Post-surgery, the patient underwent a treatment regimen that included 7 days of ceftriaxone and metronidazole, followed by 12 days of piperacillin/tazobactam (3×4.5 g IV) and 9 days of ciprofloxacin (2×500 mg orally). The treatment concluded with the patient being discharged on a course of levofloxacin (1×750 mg orally) and metronidazole (3×500 mg orally).

During follow-up, he sought care at the Infectious Diseases Department of our hospital due to a persistent cough and yellow-colored sputum. Physical examination at the time revealed no findings except fine crack-

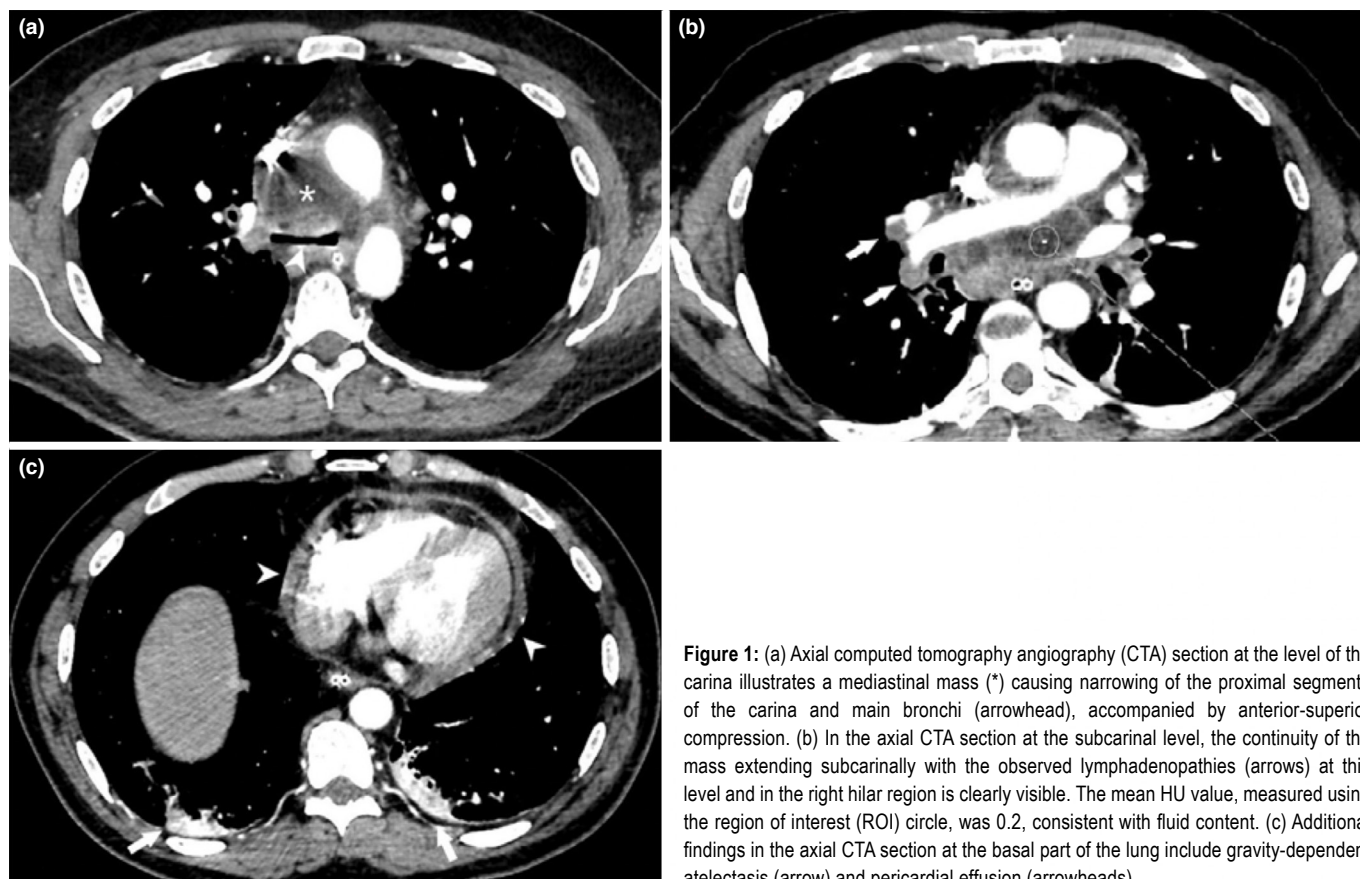


Figure 1: (a) Axial computed tomography angiography (CTA) section at the level of the carina illustrates a mediastinal mass (*) causing narrowing of the proximal segments of the carina and main bronchi (arrowhead), accompanied by anterior-superior compression. (b) In the axial CTA section at the subcarinal level, the continuity of the mass extending subcarinally with the observed lymphadenopathies (arrows) at this level and in the right hilar region is clearly visible. The mean HU value, measured using the region of interest (ROI) circle, was 0.2, consistent with fluid content. (c) Additional findings in the axial CTA section at the basal part of the lung include gravity-dependent atelectasis (arrow) and pericardial effusion (arrowheads)

les in the left middle and lower lung zones. *Aspergillus flavus* was cultured from the sputum of the patient, who had recurrent symptoms and a previous pathology report indicating fungal/hyphae spores. A preliminary diagnosis of fungal pneumonia prompted the initiation of Amphotericin B treatment at 3 mg/kg/day IV. However, the patient opted for a discharge on the 12th day of treatment. Amphotericin B was discontinued, and the patient transitioned to maintenance treatment with oral voriconazole. The patient was referred to the Ear, Nose, and Throat (ENT) department due to hoarseness. A Magnetic Resonance Imaging (MRI) of the neck yielded the following report: "Peripheral contrasting collection with a diameter of 2.5×1.5 cm in the right anterior thoracic wall suggests persistence of the infection in a patient followed up with fungal mediastinitis." Blood cultures and mycobacteriological cultures showed no growth. However, on the 15th day of hospitalization, *Pseudomonas aeruginosa* was cultured from the sputum. Anti-HIV serology, conducted due to recurrent microbiological growths, yielded negative results. Treatment with ciprofloxacin, voriconazole, and trimethoprim- sulfamethoxazole was

tailored according to microbiological tests. A follow-up CTA performed one month after discharge revealed persistent mass with partial regression. Consequently, the patient was readmitted to the clinic due to ongoing symptoms. *Pseudomonas aeruginosa* was isolated from the bacteriological culture obtained during the control bronchoscopy, while the pathology report indicated: "The morphology of mycotic elements is compatible with *Aspergillus*." Piperacillin/tazobactam (3×4.5 g IV) was transitioned to ceftazidime (3×2 g IV) on the second day, prompted by antibiotic susceptibility test results indicating resistance in the causative agent. Ceftazidime treatment was completed over 10 days, and upon discharge, the patient was advised to continue voriconazole therapy. Given the persistent hoarseness during this period, voice therapy was continued.

In light of the lack of significant symptom improvement and non-response to effective treatment, the patient underwent an assessment for immunodeficiency, involving a comprehensive array of investigations. These included a peripheral smear, lymphocyte panel, primary immuno-

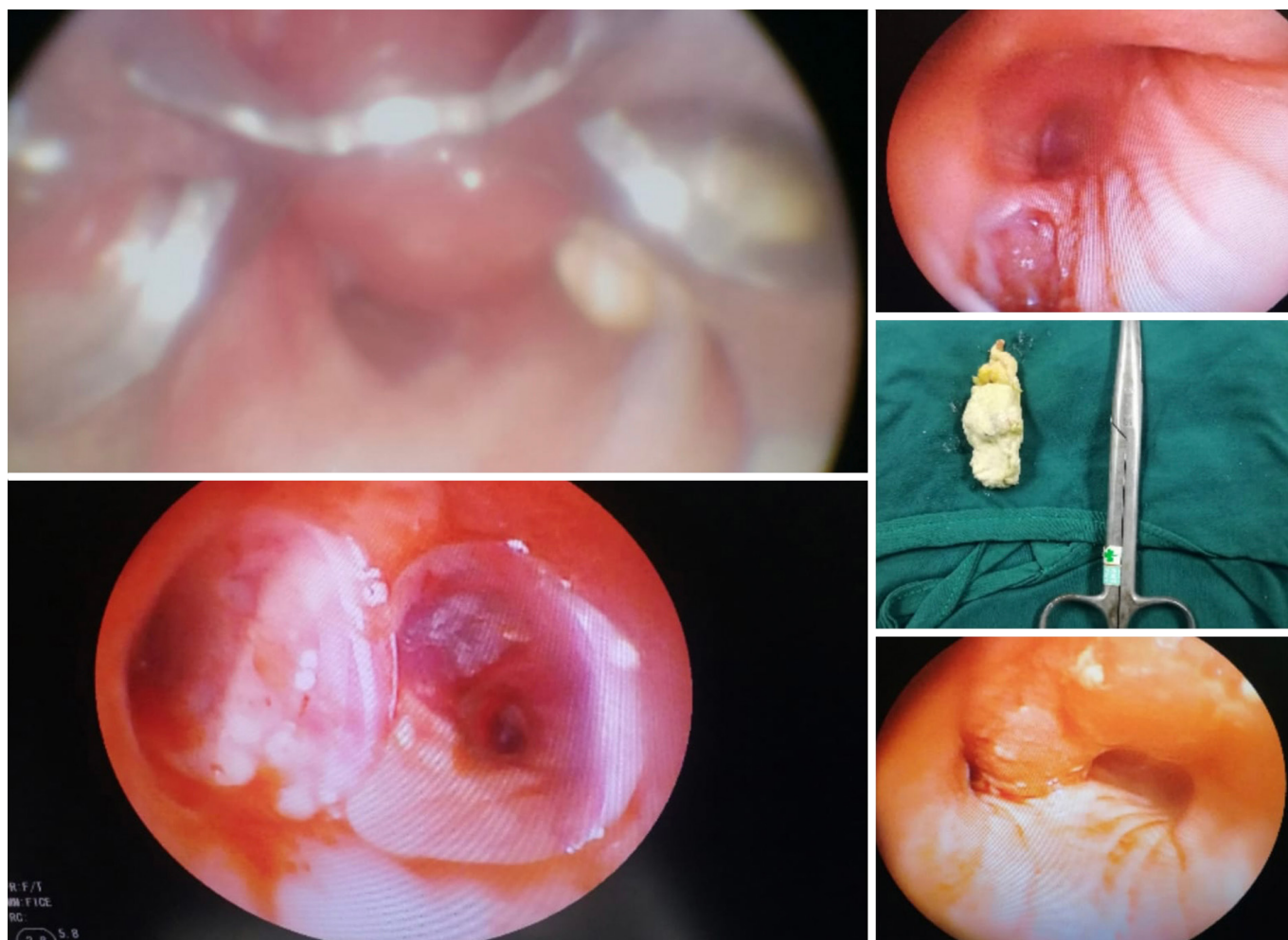


Figure 2: The necrotic lesion was removed using electrocautery, followed by the placement of a Y stent via interventional bronchoscopy

deficiency gene panel, tetanus antibody test, B memory panel, advanced T panel, and immunoglobulin subtype testing, which collectively revealed no evidence of immunodeficiency. Subsequent follow-up bronchoscopy revealed a fistula in the medial part of the right main bronchus, along with a necrotic lesion causing a 50% narrowing of the right main bronchus. Electrocautery was utilized to excise the necrotic lesion, followed by the placement of a Y stent via interventional bronchoscopy [Fig. 2]. The Y stent was removed in the follow-up. Pathological examination confirmed the presence of an invasive mycotic infection. A control CT scan conducted in June 2023, while the patient continued voriconazole and quinolone treatment, displayed regression in the mass and LAPs, along with the disappearance of carina compression [Fig. 3]. Given the absence of respiratory symptoms and radiological abnormalities on the control CT scan, antimicrobial treatment was discontinued. How-

ever, subsequent sputum culture revealed the growth of *Pseudomonas aeruginosa* and *Aspergillus flavus/oryzae*. The patient was discharged and underwent follow-up care. A consent form was obtained from our case.

Discussion

Aspergillus spp. typically causes infections in immunosuppressed individuals, though it may occasionally act as a causative agent in immunocompetent individuals, as observed in our case. We evaluated our case as immunocompetent because the patient's diabetes was under control. *Aspergillus* produces aflatoxin, a mycotoxin found in various food sources, including hard-shelled fruits, corn, peanuts, figs, red pepper, spices, milk, dairy products, and rice bran. Clinical presentations can range from rhinitis to aspergillosis, with the respiratory system being the primary route of entry and site of infection in most

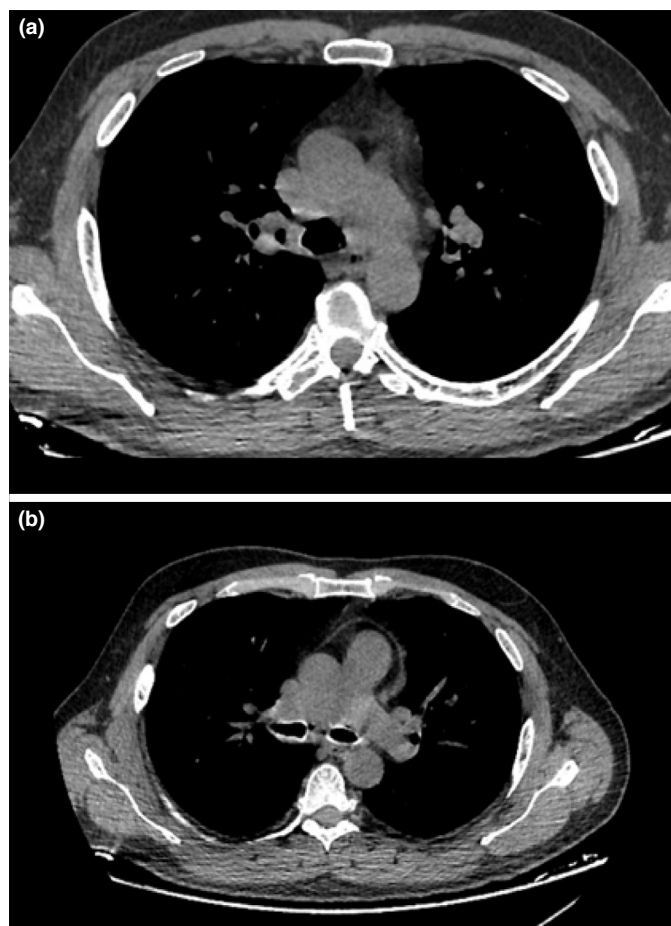


Figure 3: Follow-up CTA reveals a regression of the mass and lymphadenopathies (LAPs), along with the disappearance of carina compression. (a) Trachea level (b) carina level

CTA: Computed tomography angiography

cases. Symptoms and signs vary depending on the degree of tissue invasion by the organism and the host's immune response, which determine the extent of destruction.

Mediastinitis typically occurs following mediastinal or cardiac surgery but can also result from trauma or the spread of oropharyngeal, pulmonary, or intra-abdominal infections to the mediastinum. Gram-positive cocci such as *Staphylococcus aureus* and *Staphylococcus epidermidis* commonly cause post-surgical mediastinitis. Less frequently encountered agents include *Escherichia coli*, *Klebsiella spp.*, *Pseudomonas aeruginosa*, *Enterococcus faecalis*, and *Serratia marcescens*.^[7] Cases of granulomatous mediastinitis due to tuberculosis and fungal infections have also been documented.^[8] Although mediastinitis caused by yeasts in fungal infections is rare, it is associated with high mortality rates. Mediastinitis caused by mold fungi is even rarer.

In Brazil, it was reported that a 74-year-old patient with *Aspergillus* mediastinitis following cardiac surgery was successfully treated with long-term voriconazole and surgical intervention. A literature review revealed three additional cases of *Aspergillus* mediastinitis after coronary artery bypass surgery between 2000 and 2020, all in patients over 50 years of age and immunocompetent. Treatment, particularly with voriconazole, was successful in two cases, but one patient passed away.^[9] In another case, prolonged diagnostic procedures for a clinical and radiological presentation of mediastinal abscess and LAP led to fistulization and disruption of bronchial structure. In such instances, we believe that restoring bronchial integrity and closing the fistula, alongside medical treatment, significantly contributes to survival.

Similar to our case, there is a case report detailing the experience of a 78-year-old immunocompetent patient who underwent multiple assessments due to cough and hemoptysis lasting for 5 years. Eventually, the patient was diagnosed through video thoracoscopy and biopsy and subsequently treated with oral voriconazole.^[10] In conclusion, while less common in immunocompetent patients, *Aspergillus* should be considered in cases lacking clinical response despite appropriate treatment, and underlying risk factors should be carefully evaluated.

Informed Consent

Written informed consent was obtained from the patient for the publication of the case report and the accompanying images.

Authorship Contributions

Concept – M.I.T., M.S.T., M.H.Ö.; Design – M.I.T., M.S.T., M.H.Ö.; Supervision – M.I.T., M.S.T., M.H.Ö., A.Ç.; Funding – D.K., P.Ç.; Materials – D.K., P.Ç.; Data collection &/or processing – D.K., P.Ç., A.Ç.; Analysis and/or interpretation – M.I.T., M.S.T., M.H.Ö., A.Ç., D.K.; Literature search – D.K., P.Ç.; Writing – D.K., P.Ç., A.Ç.; Critical review – M.I.T., M.H.Ö., M.S.T.

Conflicts of Interest

There are no conflicts of interest.

Use of AI for Writing Assistance

No AI technologies utilized.

Financial Support and Sponsorship

Nil.

Peer-review

Externally peer-reviewed.

References

1. Cadena J, Thompson GR 3rd, Patterson TF. Aspergillosis: Epidemiology, Diagnosis, and Treatment. *Infect Dis Clin North Am* 2021;35(2):415–34. [\[CrossRef\]](#)
2. Blum MD, Wiedermann BL. Aspergillus infections. In: Feigin RD, Cherry JD, Demmler GJ, Kaplan SL, eds. *Textbook of Pediatric Infectious Diseases*. 5th ed. Philadelphia: Saunders; 2004:2550–60.
3. Hajjeh RA, Warnock DW. Aspergillus species. In: Long SS, Pickering LK, Prober CG, eds. *Principles and Practice of Pediatric Infectious Diseases*. 2nd ed. Philadelphia: Churchill Livingstone; 2003. p.1213–20.
4. Allam MF, Del Castillo AS, Díaz-Molina C, Navajas RF. Invasive pulmonary aspergillosis: identification of risk factors. *Scand J Infect Dis* 2002;34(11):819–22. [\[CrossRef\]](#)
5. Cuenca-Estrella M, Bassetti M, Lass-Flörl C, Ráčil Z, Richardson M, Rogers TR. Detection and investigation of invasive mould disease. *J Antimicrob Chemother* 2011;66 Suppl 1:i15–24. [\[CrossRef\]](#)
6. Çuhadar T, Kalkancı A, Tunçcan Güzel Ö, Yeğın ZA, Özkurt ZN, Köktürk N, et al. Comparison of the Results of Galactomannan and Beta Glucan Antigen Tests in the Suspicion of Invasive Pulmonary Aspergillosis. *Mikrobiyol Bul* 2023;57(2):274–82. Turkish. [\[CrossRef\]](#)
7. Tünay H, Demirdal T. Mediasten Enfeksiyonlar. *Türkiye Klinikleri J Pulm Med-Special Topics* 2013;6(1):41–5.
8. Kahya Y, Görgüner F, Yüksel C. Mediastinitler. Gürsoy S. *Göğüs Cerrahisinde Videotorakoskopi Uygulamaları*. 1st ed. Türkiye Klinikleri; 2021. p.76–80.
9. Monteiro OMC, Higa Júnior MG, Palhares MA, Nunes MO, Melhem MSC, Chang MR. A Rare Case of Aspergillus Mediastinitis After Coronary Artery Bypass Surgery: A Case Report and Literature Review. *Am J Case Rep* 2021;22:e933193. [\[CrossRef\]](#)
10. Wightman SC, Kim AW, Proia LA, Faber LP, Gattuso P, Warren WH, et al. An unusual case of Aspergillus fibrosing mediastinitis. *Ann Thorac Surg* 2009;88(4):1352–4. [\[CrossRef\]](#)